

Magnetic resonance and spectroscopic imaging in prenatal alcohol-exposed children: Preliminary findings in the caudate nucleus

Bernadette M. Cortese^a, Gregory J. Moore^{a,g}, Beth A. Bailey^f, Sandra W. Jacobson^c,
Virginia Delaney-Black^d, John H. Hannigan^{b,e,*}

^a Department of Psychiatry, Pennsylvania State University, College of Medicine Hershey, PA, 17033, USA

^b Department of Obstetrics and Gynecology, Wayne State University School of Medicine Detroit, MI, 48201, USA

^c Department of Psychiatry and Behavioral Neurosciences, Wayne State University School of Medicine Detroit, MI, 48201, USA

^d Department of Pediatrics, Wayne State University School of Medicine Detroit, MI, 48201, USA

^e Department of Psychology, Wayne State University School of Medicine Detroit, MI, 48201, USA

^f Department of Family Medicine, East Tennessee State University Johnson City, TN, 37614, USA

^g Department of Radiology, Pennsylvania State University, College of Medicine Hershey, PA, 17033, USA

Received 14 February 2006; received in revised form 23 July 2006; accepted 4 August 2006

Available online 15 August 2006

Abstract

Magnetic resonance imaging (MRI) and magnetic resonance spectroscopic imaging (MRSI) offer unique, noninvasive methods of measuring, respectively, *in vivo* quantitative neuroanatomy and neurochemistry. The main purpose of the present study was to identify and compare the neuroanatomical and neurochemical abnormalities that are associated with prenatal exposure to alcohol in both fetal alcohol syndrome (FAS)-diagnosed children and those diagnosed with fetal alcohol effects (FAE). MR data of three age-, gender- and race-balanced groups of children, FAS-diagnosed, FAE-diagnosed and non-exposed controls, were compared. Effects of prenatal alcohol exposure, regardless of diagnosis, were found in the caudate nucleus. Specifically, a significantly smaller caudate nucleus was found for the FAS and FAE participants compared to the controls. In addition, the metabolite ratio of *N*-acetyl-aspartate to creatine (NAA/Cr), an indicator of neuronal function, in left caudate nucleus of both the FAS and FAE participants was elevated compared to the control group. Analysis of absolute concentrations revealed that the increase in the ratio of NAA/Cr was due to an increase in NAA alone. Although its exact function in the CNS is unknown, NAA is believed to be a neuronal marker due to its exclusive localization to neurons. Some also speculate a role for NAA in myelination. Elevated NAA in the prenatal alcohol-exposed participants could indicate a lack of normal program cell death, dendritic pruning and/or myelination during development. The present study demonstrates that prenatal alcohol-exposed children, with or without facial dysmorphology, have abnormal brain anatomy and chemistry. © 2006 Elsevier Inc. All rights reserved.

Keywords: Fetal alcohol syndrome; Magnetic resonance imaging spectroscopy; Caudate nucleus

1. Introduction

Brain anomalies may be the defining feature of the effects of prenatal alcohol exposure given that many children exposed to prenatal alcohol have central nervous system (CNS) anomalies and deficits but not necessarily the characteristic facial features of fetal alcohol syndrome (FAS) [5,10,66]. For example, a recent study reported that even children without the characteristic FAS face demonstrate prenatal alcohol-associated neurodevelopmental

damage, including IQ deficits [33,44]. The dysmorphic facial features appear to arise only when high peak blood alcohol levels (BALs) occur during a relatively short, early period of embryonic maturation [71]. Even when the face is involved after prenatal alcohol exposure, the defining features become less distinct and the overall “gestalt” becomes unclear as the affected children pass through adolescence [68]. In contrast, CNS malformations and dysfunctions can arise from alcohol exposure occurring throughout gestation [38] and are arguably of much greater life-long consequence than facial dysmorphology. In fact, it has long been recognized that the CNS dysfunctions caused by alcohol’s teratogenic impact on brain are likely the most devastating sequelae of prenatal alcohol exposure [10,55,69].

* Corresponding author. Departments of Obstetrics and Gynecology, Wayne State University School of Medicine Detroit, MI, 48201, USA.

E-mail address: j.hannigan@wayne.edu (J.H. Hannigan).

Table 1
Participant characteristics

Subject	Diagnosis	Sex	Age (in years)	PSIQ	SES	Sedation (during scan)	MRI (volumetric data)	MRS (spectroscopic data)
1	FAS	F	9.8	70	35.0	N	X	X
2	FAS	M	11.2	65	17.0	N	X	X
3	FAS	M	9.6	66	25.0	Y	Removed except for correlation	X
4	FAS	M	12.3	70	14.0	N	X	X
5	FAS	F	11.8	79	30.5	N	X	X
6	FAS	M	11.9	76	33.0	N	X	X
7	FAS	F	12.0	72	38.0	N	X	X
8	FAE	M	12.7	79	30.0	N	X	Poor quality
9	FAE	M	11.2	61	32.0	N	Incomplete	X
10	FAE	M	11.2	78	25.0	Y	Removed except for correlation	X
11	FAE	F	11.3	80	19.0	N	X	Incomplete
12	CNTRL	M	11.4	91	19.0	N	X	X
13	CNTRL	F	12.2	101	22.0	N	X	X
14	CNTRL	M	11.2	98	51.0	N	X	X
15	CNTRL	F	12.0	84	30.0	N	X	X

FAS: fetal alcohol syndrome, FAE: fetal alcohol effects, CNTRL: healthy controls, PSIQ: performance scale IQ, SES: Hollingshead Index.

The “FAS characteristic face” may fail as a screening tool because it can yield a high rate of false negatives [59] in identifying fetal alcohol-affected individuals. Even though the pattern of craniofacial alterations is fairly specific to alcohol [11,26], the anomalies cannot, of course, be used to identify prenatal alcohol-affected individuals who do not present with the characteristic FAS face. Many have confirmed the association between maternal drinking and persistent, complex neurobehavioral deficits in children in the absence of altered facial features, including difficulty with abstract reasoning, planning, attention, working memory and slower cognitive processing speed (e.g., [29,31,40,49,70]). This suggests that, compared to facial features, neurobiological outcomes may more effectively characterize and categorize fetal alcohol-affected individuals. Neurobiological characterization of CNS involvement is critical for three reasons: to better understand the core deficits, not only in FAS, but across the fetal alcohol spectrum disorders (FASDs), to objectively diagnose these effects, and ultimately to assess treatment effectiveness for the life-long CNS dysfunctions.

Magnetic resonance imaging (MRI) and magnetic resonance spectroscopic imaging (MRSI) provide unique, noninvasive methods of measuring *in vivo*, quantitative neuroanatomy and neurochemistry, respectively. MR imaging has the capability to identify biological indices of compromised CNS development resulting from prenatal alcohol exposure for a wide range of affected individuals. For example, the earliest clinical reports of the teratogenic effects of alcohol on the developing brain came from autopsy studies [10,73]. These studies only reported on children who were highly exposed and the most severely affected by prenatal alcohol, to the point of death. Since imaging techniques allow non-invasive *in vivo* access to the brain, researchers can describe neuroanatomical and neurochemical abnormalities of living subjects exposed to a much wider range of prenatal alcohol exposures than are represented at autopsy. In addition, the range of neuroanatomical and neurochemical effects of this exposure can also be studied on a continuum, meaning that relatively less affected subjects can be assessed. Imaging techniques can also provide more sophisticated analyses than are possible with gross post-mortem autopsy.

This means that early, detailed identification of structural or functional anomalies may yield not only biomarkers necessary for a confirmed diagnosis of FAS, but also the *sensitivity* needed to discriminate FAS from among the other FASDs. To date, a number of quantitative MRI studies have reported significant effects of prenatal exposure to alcohol in corpus callosum, caudate nucleus and cerebellum among other cortical and subcortical brain regions. See two excellent recent reviews by Riley et al. [52,54]. Specific effects include reduced overall brain size (i.e., intra-cerebral volume), dysgenesis or partial to complete agenesis of the corpus callosum [53], reduced volume of the caudate nucleus [43] and cerebellar abnormalities including decreased volume with a disproportionate reduction in the region of the anterior vermis [65]. Some aspects of altered brain shape originally identified with MR have been reported also using ultrasound imaging of prenatal alcohol-exposed infants [7,72]. Although these imaging studies have provided important information on the impact of prenatal exposure to alcohol on brain structure, functional imaging studies are also of great importance, as differences in brain size and/or shape may not directly identify functional deficits.

The objectives of the present preliminary study were to establish the feasibility of MRSI in prenatal alcohol-exposed children and to identify CNS neurochemical indices associated with prenatal alcohol exposure. These neurobiological measures, along with more traditional neuropsychological tests, may be used together to allow an early definitive diagnosis of FASDs such as FAS and alcohol-related neurodevelopmental disorder (ARND). This possibility is especially important for individuals who do not exhibit the characteristic FAS facial “phenotype” but still have functional disabilities due to prenatal alcohol-induced effects on CNS development.

2. Methods

2.1. Participants

Three small groups of children were enrolled in the present study, selected largely from two prospectively recruited cohorts of

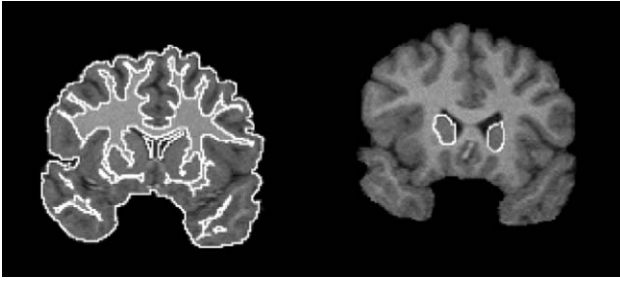


Fig. 1. Tracings of intracranial volume (left) and head of the caudate nucleus (right) used for regional volume calculations.

prenatal alcohol-exposed infants born in a large inner-city maternity hospital in the late 1980s and early 1990s [15,28,32]. The groups were defined on the basis of prenatal alcohol exposure and facial dysmorphism. Group 1 (FAS-diagnosed) consisted of seven children with facial dysmorphism that were exposed to moderate to high levels of prenatal alcohol. Diagnosis was confirmed by a pediatric genetics physician trained specifically in diagnosis of FAS. Group 2 ($n=4$) also had moderate to high levels of prenatal alcohol exposure, but did not meet the criteria for FAS due to a lack of facial dysmorphism, and was therefore labeled FAE. Based on maternal self-report, the control participants (group 3, $n=4$) were not believed to have been exposed to prenatal alcohol and had no dysmorphic features. As much as possible, the children in group 2 and group 3 were selected to match group 1 for gender and age. The specific characteristics of these children are presented in Table 1.

The prospective recruitment of the original two cohorts, the assessment of maternal self-report of alcohol consumption throughout pregnancy and descriptions of the cohorts' characteristics were detailed by Drs. Jacobson [28,32] and Delaney-Black [13] and in many subsequent publications from these laboratories (e.g., [3,14,15,29,30]). Briefly, a structured interview designed initially by Sokol et al. [62] to assess alcohol use in pregnancy was adapted and administered to all women seeking prenatal care during their first visit to the antenatal clinic of a large, inner-city women's hospital serving primarily African-American women (92%). During this interview, the Michigan Alcoholism Screening Test [60] and the T-ACE or TWEAK problem drinking screens [56,57,63] were administered along with specific questions concerning day-to-day drinking around the time of conception and during the 2 weeks prior to each visit to the clinic. Moderate and heavy drinking women were over-represented in the two cohorts, and a pseudo-random sample of an equal number of lower-level drinkers and abstainers was also invited to participate [13,28,32]. Other key data collected from the women in both cohorts included personal (e.g., SES, education, age, etc.), medical and environmental information, and other drug use/abuse during pregnancy, especially cigarette smoking and cocaine use [13].

2.2. Procedure

Participants ranging in age from 9 to 12 years at the time of testing were brought to the MRI Scanning Facility located at the Children's Hospital of Michigan, Detroit Medical Center. All MR exams were performed using a 1.5-T clinical scanner (GE Signa,

Horizon hardware, 5.7 Software). Participants were placed in the scanner with their head positioned and stabilized in the quadrature radio frequency head coil (GE Medical Systems). Each participant was made as comfortable as possible by using earplugs and headphones to reduce noise, adjusting light and airflow through the magnet, having a familiar person present in the room, and using a mirror system to allow the participant a view outside of the magnet. In addition, participants were provided with an audio link to an MR nurse who gave guidance and support. Each scanning session lasted between 60 and 90 min. All procedures had prior approval of the Wayne State University Human Investigation Committee. Written, informed consent of the parent or legal guardian and verbal assent of the child was obtained in each case.

2.2.1. MRI acquisition and analysis

For volumetric data acquisition, a three-dimensional "spoiled" gradient echo sequence (SPGR) was used. This sequence yielded 124 contiguous slices (1.5 mm thick) of anatomical data in the coronal plane (TE 5 ms, TR 25 ms, acquisition matrix 256×256 , field of view = 24 cm, flip angle = 10°). All MRI scans were first visually inspected and excluded if judged by a trained technician to be of poor quality with either evidence of magnetic field inhomogeneities and/or significant motion artifact. Imaging data were transferred to a workstation and the National Institute of Health (NIH) IMAGE software (version 1.61) was used to compute all neuroanatomical measurements. This method required circumscribing the structure of interest over successive brain slices using a stylus-controlled cursor (Fig. 1). A semi-automated threshold technique based on signal intensity was used to define gray and white matter and CSF [34]. Volumes of gray and white matter were then individually estimated and added to compute total volume. All measurements were performed by a single, trained rater (inter-rater reliability = 0.96–0.99) blind to any identifying subject information. Intra-class correlations of intra-rater reliability ranged from 0.98 to 0.99. The following brain measurements were traced and calculated as described below.

2.2.1.1. Intracranial volume (ICV). The entire brain, excluding cerebellum and brainstem, was traced on all odd slices, numbering approximately 62. Area measurements were computed for each tracing, added together and multiplied by twice the slice thickness to estimate intracranial volume. Gray and white matter volumes, excluding cerebral spinal fluid (CSF) in the ventricles and sulcal spaces, were calculated separately and then added for a measure of total ICV.

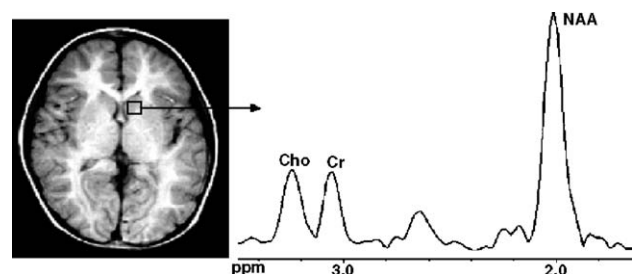


Fig. 2. Illustration of the processed neurochemical data acquired for the left caudate nucleus.

2.2.1.2. Caudate nucleus. The left and right caudate nuclei (gray matter) were measured separately by outlining approximately 30 successive, contiguous slices through this area. The following boundaries were used to trace the caudate nucleus: The medial border was the lateral ventricle, while the caudate was laterally separated from the globus pallidus and putamen by white matter tracts (internal capsule). The superior border of the caudate nucleus was the body of the corpus callosum, which merges inferiorly with the nucleus accumbens and putamen.

2.2.2. MR spectroscopic image acquisition and analysis

Proton magnetic resonance spectroscopic imaging ($^1\text{H-MRSI}$) uses the same basic instrument and principles as conventional MRI but differs in that it uses gradient radiofrequency pulse sequences to suppress the water signal and acquire select, localized metabolic profiles as spectroscopic images of brain [45]. Clinical research studies using $^1\text{H-MRSI}$ measure the concentrations of choline compounds (Cho), creatine/phosphocreatine (Cr) and *N*-acetyl compounds, predominately the neuron-specific *N*-acetyl-aspartate (NAA), among others that are indicative of neurological pathology [12].

First, T1-weighted MR images (15 mm thick, TE 20 ms, TR 400 ms) were recorded at the same four axial slice locations as the neurochemical data set: The first slice was chosen at the level of the third ventricle, the second slice showed the lateral ventricles, the third slice contained the centrum semiovale, and the fourth slice consisted exclusively of cortical gray matter. These images were used for anatomical localization of the caudate prior to being analyzed neurochemically by MRSI. The MRSI procedure used to acquire the neurochemical data is detailed elsewhere [19]. Briefly, a chemical shift-selective (CHESS) saturation pulse was used for water suppression, and an outer-volume-saturation sequence (OVS) was used for suppression of signals originating from lipids in the skull and scalp. Section selection was made using a spin-echo sequence. Specifically, four 15-mm-thick slices with an inter-slice gap of 2.5 mm were obtained (TE 280 ms, TR 2300 ms). The field of view was 24 cm \times 24 cm, which yielded a nominal voxel size of 15 \times 8 \times 8 mm (0.8 cm³).

Imaging data were transferred to a workstation running Solaris 2.7 for quantitative spectral analyses using a semi-automated, non-linear, least squares curve fitting procedure (IMAX and CSX software, Dr. P. Barker, Johns Hopkins University). The caudate nucleus was located from the MR locator image and analyzed (Fig. 2). Once selected, the corresponding neurochemical spectra were displayed, showing the peaks of Cho, Cr and NAA pertaining to that region. Each biochemical was identified using the prominent NAA peak as a reference and picked according to their resonant frequencies (e.g., Cho = 3.23 ppm, Cr = 3.02 ppm and NAA = 2.02 ppm). The curve-fitting procedure provided quantitative area-under-the-peak measurements that corresponded directly to the concentration of each chemical within the caudate nucleus.

In the present study, absolute concentrations of chemicals were calculated using a “phantom replacement” method [61]. Briefly, a 2-L polypropylene ball was made containing a solution of 50 mM Cr, 56 mM NaCl, 50 mM potassium

phosphate buffer (KH₂PO₄ and K₂HPO₄) and 2.1 ml gadolinium (Gd), a contrast agent, in double-distilled water (DDH₂O). This phantom was placed in the scanner and imaged using the same methodology for MRSI discussed above, to generate a standard peak for the known concentration of Cr. All *in vivo* neurochemical concentrations were estimated from the known Cr standard.

3. Results

3.1. Clinical data: neuroanatomical study

When comparing brain volume among groups and, in the absence of sufficient numbers of participants to assess gender effects, it was important for this preliminary study that the groups were balanced on gender as overall brain size and most sub-cortical structures are bigger for males than for females [18]. The caudate nucleus is one of the few brain regions that is similar in absolute size for both males and females and is therefore normally considered “disproportionately” large in females when overall brain size is taken into account [8]. This was one reason for selecting similar male-to-female ratios among the control, FAS and FAE groups for these neuroanatomical analyses (Table 1). In addition to group matching on gender, Filipek advocates adequately matching on other important subject variables including age, ethnicity, IQ and SES in developmental neuro-imaging research [21]. Specifically, the control group (group 3) consisted of 4 (50% male) children not exposed prenatally to alcohol with a mean age of 11.7 years (range = 11.2–12.2 years). All of the children in the group 3 controls successfully completed the MR examination without sedation. Furthermore, all of the MR data from this group were of good quality.

Similar to the controls, all of the FAS-diagnosed participants (group 1) successfully completed the MR examination without sedation, and all of the MR data from this group 1 were of good quality. Due to recruitment difficulties, however, the two alcohol-exposed groups were not balanced on gender as was the control group. To balance group 1 (FAS) by gender, the anatomical data from one of the male FAS participants, chosen according to age to maintain the match with control, were removed from this analysis. The FAS group for the anatomical analyses, therefore, consisted of six FAS-diagnosed children with a mean age of 11.5 years (range = 9.8–12.3 years); three of the six (50%) were male.

Unlike any participants from the FAS and control groups, one FAE-diagnosed participant (group 2) experienced a claustrophobia-like reaction and asked to be removed from the scanner before the anatomical data could be collected. The anatomical data from a male FAE participant, also chosen according to age, were removed to maintain the gender balance among the groups. For the neuroanatomical analyses, the FAE group was limited to two children (one male) with a mean age of 12.0 years (range = 11.3–12.7 years).

Independent *t*-tests were used to assess differences in the neuroanatomy and neurochemistry of the prenatal alcohol-exposed groups compared to the controls. With the limited sample sizes in

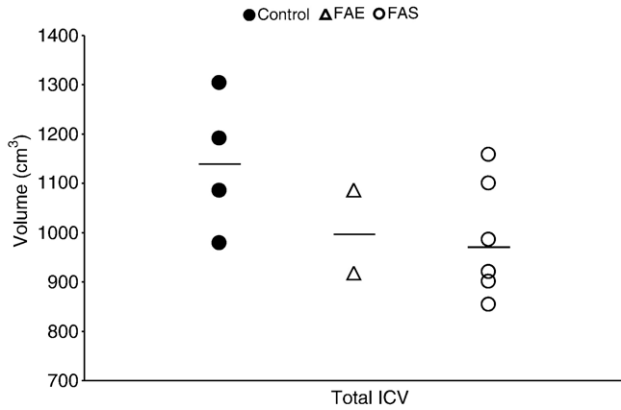


Fig. 3. Non-significant decreases in intracranial volume (ICV) in the FAS and FAE participants compared to the controls. Individual participants are depicted (symbols) together with the group means (bars). The controls are filled circles (●), the individuals in the FAE groups are open triangles (▲), and the FAS children are depicted with open circles (○).

this preliminary, exploratory investigation, and to decrease the risk of making a type II error, a less conservative approach was utilized for statistical analysis. Therefore, in addition to using *t*-tests versus ANOVA, the Bonferroni correction was not applied and a *p*-value of ≤ 0.05 was used.

3.2. MR data: neuroanatomical study

One-tailed independent *t*-tests revealed a marginally significant smaller (13%) overall brain volume (ICV) for the FAS-diagnosed group ($t_{(df=8)}=1.86, p=0.099$) and a non-significant, 12% smaller ICV for the FAE-diagnosed group, both compared to the controls (Fig. 3). Statistically significant smaller volume for both the left (15%) and right (13%) caudate nuclei ($t_{(df=8)}=3.46, p=0.009$; $t_{(df=8)}=2.34, p=0.047$, respectively) were found in the FAS group compared to the control group using one-tailed independent *t*-tests (Fig. 4). A significant reduction in total ICV indicates that individual brain areas within the ICV are also likely to be smaller. To limit redundant representation of significant effects and to assess if

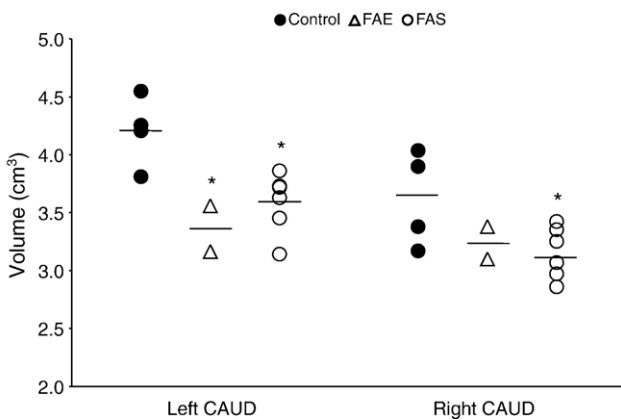


Fig. 4. Significant decreases in the left and right caudate nucleus of FAS and FAE participants compared to the controls. Individual participants are depicted (symbols) together with the group means (bars). The * indicates significant difference from respective control group at $p < 0.05$.

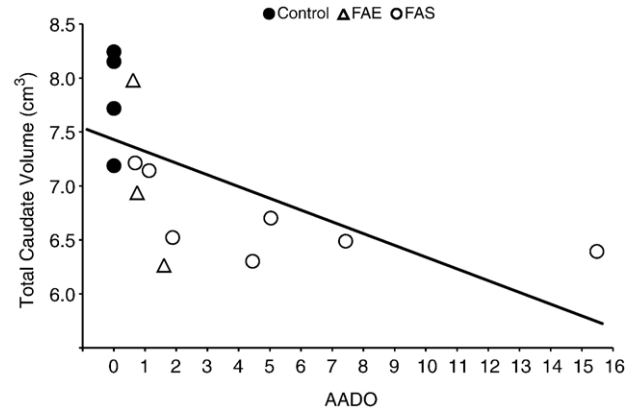


Fig. 5. Significant negative correlation ($r=-0.578, p=0.03$) between the alcohol exposure variable AADO (ounces of absolute alcohol/day at the time of conception) and total volume of caudate nucleus (collapsed on side). Individual participants are depicted (symbols) together with the overall regression line.

individual areas may be disproportionately affected by alcohol, we also controlled for differences in total ICV, as has been done in previous studies (e.g., [42,43]). When the effect of prenatal alcohol exposure on overall brain size was taken into account with a covariate analysis, the volumes of the left and right caudate nucleus were no longer significantly smaller than the controls. For the most part, the smaller caudate nucleus volumes demonstrated in the FAE group compared to the controls were less than the reductions found in the FAS group and not statistically different from controls (Figs. 3 and 4) except that the left caudate was significantly smaller for the FAE group compared to the control group ($t_{(df=8)}=3.27, p=0.015$).

Prospective quantitative information on prenatal maternal alcohol consumption allowed the assessment of the dose-dependency of the significant decreases in the size of the caudate nucleus. Among all of the prenatal alcohol-exposed ($n=10, 7$ FAS, 3 FAE) and the non-exposed participants ($n=4$) who had good quality volumetric data, there was a significant negative correlation between the reported amount of absolute

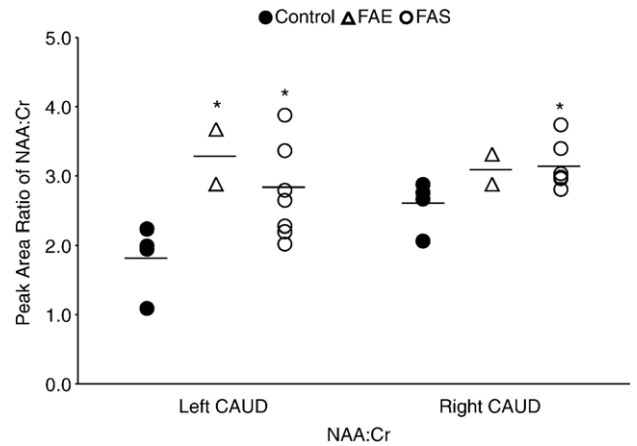


Fig. 6. Significant increases in peak area ratio of NAA/Cr in the left and right caudate nucleus of FAS and FAE participants compared to the controls. Individual participants are depicted (symbols) together with the group means (bars). The * indicates significant difference from respective control group at $p < 0.05$.

alcohol consumed around the time of conception and total caudate nucleus volume ($r=-0.578$, $p=0.03$; Fig. 5).

3.3. Clinical data: neurochemical study

Previous studies have shown no significant effects of gender on the MR-measured neurochemicals in the caudate nucleus, in particular for the ratio of NAA/Cr in basal ganglia [9,35,51]. Therefore, the decision was made to include all available data for the neurochemical analyses, regardless of the gender of the participants. The prenatal alcohol-exposed groups and the control group were comprised as follows (Table 1).

The six FAS participants who were used in the neuroanatomical study plus one additional FAS participant were included in the neurochemical study so that the final FAS group consisted of seven FAS-diagnosed children with a mean age of 11.2 years (range=9.6–12.3 years); four of the seven (57.1%) were male. The two FAE participants who participated in the neuroanatomical study did not have usable neurochemical data due to excessive movement artifact for one child and missing data for another who ended the MR session early due to a claustrophobic-like response. Therefore, the final FAE group was comprised of two FAE-diagnosed children that were both 11.2 years old; both were male and one was sedated during the MR examination. The same four control participants that were used for the neuroanatomical analyses were used and provided good-quality neurochemical data for the analyses: four non-prenatal alcohol-exposed children (50% male) with a mean age of 11.7 years (range=11.7–12.2 years).

3.4. MR data neurochemical study

Neurochemical analysis revealed significant elevations in the ratio of NAA/Cr in the left and right caudate nucleus of the FAS group compared to the control group ($t_{(df=9)}=2.37$, $p=0.04$ and $t_{(df=9)}=2.53$, $p=0.03$; Fig. 6). There were no marked differences in the Cho/Cr ratio. Absolute quantification of neurochemicals revealed no differences in Cho or Cr levels between the FAS

participants and the controls. However, there were higher levels of NAA in both the left and right caudate of the FAS group compared to the controls. Two-tailed independent t -tests revealed that this elevation in the left caudate nucleus was statistically significant ($t_{(df=9)}=3.06$, $p=0.01$; Fig. 7). Similar to the FAS group, the two FAE participants had a large, statistically significant elevation in the ratio of NAA/Cr in the left caudate nucleus ($t_{(df=4)}=3.28$, $p=0.03$) compared to the control group.

4. Discussion

The results of the present study demonstrate that MRI and MRSI scans can be conducted effectively in prenatal alcohol-exposed children, and almost all without sedation. This successful scanning in children with FASDs is significant because prenatal alcohol-exposed children commonly present with other comorbid psychiatric diagnoses including hyperactivity, anxiety and conduct disorders [50], any of which may preclude these children from MR studies due to the demands of the imaging process. Although increasingly sophisticated structural MR imaging in prenatal alcohol-exposed children has been done before [1,41–43,48,55], the present study is the first to acquire MRSI neurochemical data in this population. This is significant because the MRSI sequence alone used in the present study required participants to remain still for a full 30 min, whereas other MR anatomical scanning sequences often average only 7 to 10 min. Successful scanning with the present protocols suggest that other MR imaging procedures requiring unsedated, alert and mentally active participants (especially fMRI) may be possible in prenatal alcohol-exposed children.

Volumetric analysis of the children diagnosed with FAS revealed an overall 13% smaller brain size compared to the brains of an age- and gender-balanced group of controls. Furthermore, the two FAE participants demonstrated a similar (12%) smaller overall brain size. These results parallel those previously published in both laboratory animal [37,39] and human autopsy studies [10,36]. These results are also remarkably similar to another MR study that reported an approximate 11% reduction in the gray and white matter of the cerebral (i.e., supratentorial) vault in the FAS-diagnosed participants, and about a 6% reduction in their prenatal exposure to alcohol group (PEA) compared to age-appropriate healthy controls [1].

A disproportionate smaller size of the basal ganglia was among the first reported findings with structural MRI in prenatal alcohol-exposed individuals [41–43]. A significantly smaller caudate nucleus was found in the two alcohol-exposed groups in the present study compared to the non-exposed controls. Specifically, the left and right caudate nuclei in the FAS participants compared to the controls were 15% and 13% smaller, respectively, a reduction similar to the 13% found for overall brain volume. Therefore, when overall brain size was taken into account in this particular small sample, this effect was no longer significant.

Neurochemical analyses revealed a significantly elevated NAA/Cr ratio in the left and right caudate nucleus of both the FAE and FAS groups compared to the non-exposed group, and the absolute quantification of NAA levels showed a significant

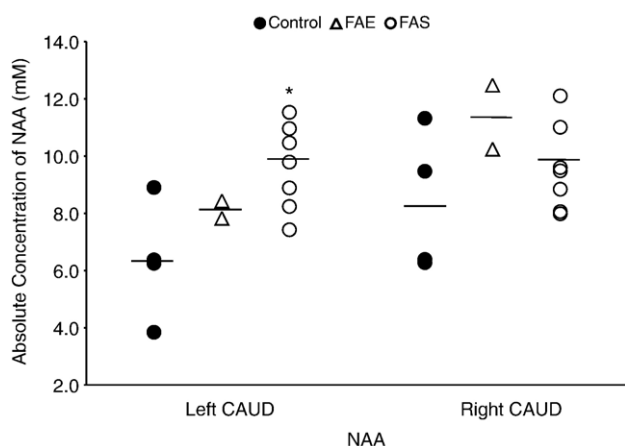


Fig. 7. Significant increases in absolute values of NAA in the left and right caudate nucleus of FAS and FAE participants compared to the controls. Individual participants are depicted (symbols) together with the group means (bars). The * indicates significant difference from respective control group at $p<0.05$.

elevation in the left caudate in the FAS participants. NAA is a highly abundant amino acid in CNS, second only to glutamate, and accounts for the most prominent peak in a ^1H -MRS spectrum from brain, although the exact role of NAA in the CNS is unknown. Many have speculated on its function and some argue that NAA may be involved in the regulation of neuronal protein synthesis, may serve as metabolic and/or storage forms of the neuromodulator/neurotransmitters *N*-acetyl-aspartyl-glutamate (NAAG) and/or aspartate [47], or may have a role in lipid synthesis for the production of myelin [6]. Another source suggests that NAA may act as a “molecular water pump” for myelinated neurons in the CNS and removes the large quantities of water produced by the oxygen metabolism of the brain [4]. Regardless of its exact function in the CNS, NAA is considered to be a valid neuronal marker because it is located in very high concentration within neurons and precursor cells, but not mature glia, cerebral spinal fluid (CSF) or blood [45]. NAA is also considered to be a reliable although non-specific indicator of neuronal dysfunction because its levels are often reduced in pathology (e.g., traumatic brain injury, stroke and demyelination disorders).

While neuronal dysfunction has traditionally been associated with a decrease in absolute concentration of NAA, the increase in NAA reported in the present study could also signify functional abnormalities and cognitive deficits. For example, Russell et al. [58] reported a significant 21% increase of NAA in the left DLPFC of medication-naïve, pediatric patients with obsessive-compulsive disorder that can be interpreted to represent a compensatory response to decreased neuronal functioning, reflected in decreased NAA levels, in other brain areas such as right medial thalamus [23] and/or anterior cingulate cortex [20].

The Cho resonance reflects both phosphorylcholine and glycerophosphorylcholine, chemicals important for lipid synthesis and cell membrane integrity [45]. Since Cho is found in much higher concentrations in glia, an increase in Cho could indicate gliosis, an overgrowth of astrocytes indicative of brain damage or tumor. Elevated Cho levels could also be symptomatic of a neurodegenerative state that results in membrane breakdown and the release of the normally immobile, membrane-bound phosphatidylcholine into a free Cho pool [46]. Since Cho levels in the brain dramatically decrease during the first 2 years of life [12], one possible reason for finding elevated choline in the brain could be a developmental delay. For example, in a study of children (ages 3–10 years) with mild developmental delays, the frontal and parietal–occipital, sub-cortical white matter ratio of Cho/Cr was higher compared to age-matched, “non-delayed” controls [22]. The authors noted that the proton MR spectra of the developmentally delayed group were more consistent with that of children younger than 2 years of age.

The Cr resonance reflects both creatine and phosphocreatine, chemicals necessary in the maintenance of high energy-dependent systems. It has been proposed, but not verified, that Cr is unaffected by brain pathology or pharmacological treatments and, despite this unconfirmed assumption, Cr is widely used as a standard for assessing changes in NAA and Cho levels [45]. For example, an elevated Cho/Cr ratio is understood to indicate a neurodegenerative disease state [12], while a lower NAA/Cr ratio is usually interpreted as increased neuronal death and/or

dysfunction in a particular brain area [6,45]. A drawback to the use of Cr as essentially an internal reference standard for other neurochemicals in the brain is that the ratios (e.g., NAA/Cr or Cho/Cr) provide a relative, rather than absolute measure of either NAA or Cho concentration.

Although many studies report changes in neurochemicals and/or neurotransmitters due to prenatal alcohol exposure in animal models [16,17,25], there is only one published MRS neurochemical imaging study of which we are aware that assessed brains exposed to prenatal alcohol [2]. That study assessed the effects of prenatal alcohol exposure in non-human primates (*macaca nemestrina*) using both MRI and MRS [2]. The authors reported no MRI-detected gross morphological abnormalities of thalamus, basal ganglia, internal capsule and adjacent white matter in either the prenatal alcohol-exposed or control animals. MRS imaging results, however, revealed a significantly elevated Cho/Cr ratio in the prenatal alcohol-exposed group compared to the non-exposed controls, an effect which was attributed to an alcohol-induced increase in Cho levels in this group, although this was not specifically measured. Furthermore, there was a trend showing that, as the duration of prenatal alcohol exposure increased, the Cho/Cr ratio increased [2]. Given the MRS-measured neurochemical changes that occur in the normal brain before age 2, those results are consistent with an hypothesis of delayed brain maturation, in general, or myelination, in particular.

In the present preliminary study, both ratios and absolute concentrations of the selected neurochemicals were acquired with the multi-voxel, MRSI technique that allowed for simultaneous acquisition of resonance signals from multiple regions of the brain. The advantages of this scanning sequence, compared to the single-voxel MRS paradigm used in the non-human primate study, include more precise spatial resolution, acquisition of data over the entire brain, and not being limited to a pre-selected single volume of interest. Furthermore, data acquired from a large, single voxel that encompasses several different brain tissues/regions, as in the non-human primate study [2], are subject to “partial voluming” effects. Partial voluming effects are less of a concern with the relatively smaller voxels used with the current MRSI technique and therefore would be of limited value for this study.

The goals of the present investigation were to determine the feasibility of MR spectroscopic imaging in prenatal alcohol-exposed children, to examine the neural structural and, particularly, chemical effects associated with this exposure, and to assess similarities and differences in the patterns of anomalies between the FAS and FAE participants. Even though there were only two FAE cases included in each of the structural MRI and the MRSI analyses in this initial study, the preliminary results in volume of the caudate nucleus demonstrate that MR imaging is sensitive to the effects of prenatal alcohol exposure in both FAS and FAE participants, similar to previous findings [1,43]. These effects of prenatal alcohol exposure on the neurochemistry of the left caudate nucleus are also comparable for children diagnosed either with FAS or FAE. Evidence from previous studies indicates that children with or without the facial features associated with prenatal alcohol exposure are susceptible to alcohol’s effects on behavior, a proven sensitive, but not necessarily specific, measure of prenatal alcohol exposure [27,64]. In general, issues of

sensitivity and selectivity are very important to diagnoses of FASDs. The characteristic FAS facial dysmorphism has high selectivity but appears to lack sensitivity to alcohol exposures that are known to produce significant neural and behavioral effects [5]. Neurobehavioral or neuropsychological assessments can be very sensitive in detecting developmental delays produced by alcohol, but despite growing consensus about common outcomes [44,67], there is debate about the selectivity of behavioral measures used to diagnose FAS and other FASDs [24]. At this stage, it is not known how selective and sensitive MR spectroscopy may be in identifying prenatal alcohol-affected children.

The present results are preliminary support for MR-measured neuroanatomical effects of prenatal alcohol exposure in the absence of dysmorphic facial features. Children with and without prenatal alcohol-associated facial dysmorphism demonstrated similar patterns of change in brain anatomy and chemistry in the present study. These results suggest that exposure to prenatal alcohol, regardless of diagnosis based on facial dysmorphism, affects MR-sensitive CNS anatomy and chemistry alike. The current preliminary results suggest that MR metabolite profiles in brain may prove to be both highly sensitive and selective in themselves, and may aid in defining more selective or focused neurobehavioral assessments, as well. Furthermore, even though the volume of the caudate nucleus was not disproportionately reduced relative to total ICV as in previous studies [41–43], there were significant changes in NAA suggesting that MRSI may be more sensitive to the functional effects of prenatal alcohol exposure than anatomical measures. Although prenatal alcohol-associated facial dysmorphism provides a relatively easy, specific and definitive diagnosis of FAS, the present results support the growing belief that the emphasis placed on facial features as a diagnostic tool may be inadequate for individuals elsewhere along the continuum of FASDs and that neurobiological indices may serve.

Acknowledgement

The research that originally recruited many of the participants was supported in part by grants R01-AA09524 to SWJ, R01-DA08524 to VDB, and by the Fetal Alcohol Research Center at Wayne State University (P50-AA07606, R.J. Sokol, Director). The present research was supported in part by grant R01-DA016373 to VDB and by the Department of Obstetrics and Gynecology at Wayne State University. The authors thank S.K. O'Leary-Moore for helpful comments on the manuscript.

References

- [1] S.L. Archibald, C. Fennema-Notestine, A. Gamst, E.P. Riley, S.N. Mattson, T.L. Jernigan, Brain dysmorphism in individuals with severe prenatal alcohol exposure, *Dev. Med. Child Neurol.* 43 (2001) 148–154.
- [2] S.J. Astley, E. Weinberger, D.W.W. Shaw, T.L. Richards, S.K. Clarren, Magnetic resonance imaging and spectroscopy in fetal ethanol-exposed *Macaca nemistrina*, *Neurotoxicol. Teratol.* 17 (1995) 523–530.
- [3] B.N. Bailey, V. Delaney-Black, C.Y. Covington, J. Ager, J. Janisse, J.H. Hannigan, R.J. Sokol, Prenatal exposure to binge drinking and cognitive and behavioral outcomes at age 7 years, *Am. J. Obstet. Gynecol.* 191 (2004) 1037–1043.
- [4] M.H. Baslow, Evidence supporting a role for *N*-acetyl-L-aspartate as a molecular water pump in myelinated neurons in the central nervous system. An analytical review, *Neurochem. Int.* 40 (2002) 295–300.
- [5] J. Bertrand, L.L. Floyd, M.K. Weber, Fetal Alcohol Syndrome Prevention Team, Division of Birth Defects and Developmental Disabilities, National Center on Birth Defects and Developmental Disabilities, Centers for Disease Control and Prevention (CDC), Guidelines for identifying and referring persons with fetal alcohol syndrome, *MMWR Recomm. Rep.* 54 (2005) 1–14.
- [6] D.L. Birken, W.H. Oldendorf, *N*-Acetyl-L-aspartic acid: a literature review of a compound prominent in H-NMR spectroscopic studies of brain, *Neurosci. Biobehav. Rev.* 13 (1989) 23–31.
- [7] F.L. Bookstein, P.D. Connor, K.D. Covell, H.M. Barr, C.A. Gleason, R.W. Sze, J.A. McBroom, A.P. Streissguth, Preliminary evidence that prenatal alcohol damage may be visible in averaged ultrasound images of the neonatal human corpus callosum, *Alcohol* 36 (2005) 151–160.
- [8] V.S. Caviness, D.N. Kennedy, J.F. Bates, N. Makris, The developing human brain: a morphometric profile, in: R.W. Thatcher, G.R. Lyon, J. Rumsey, N. Krasnegor (Eds.), *Developmental Neuroimaging: Mapping the Development of Brain and Behavior*, Academic Press, San Diego, CA, 1997, pp. 169–186.
- [9] H.C. Charles, F. Lazeyras, K.R. Krishnan, O.B. Boyko, L.J. Patterson, P.M. Doraiswamy, W.M. McDonald, Proton spectroscopy of human brain: effects of age and sex, *Prog. Neuropsychopharmacol. Biol. Psychiatry* 18 (1994) 995–1004.
- [10] S.K. Clarren, E.C. Alvord Jr., S.M. Sumi, A.P. Streissguth, D.W. Smith, Brain malformations related to prenatal exposure to ethanol, *J. Pediatr.* 92 (1978) 64–67.
- [11] L.G. Costa, M. Guizzetti, M. Burry, J. Oberdoerster, Developmental neurotoxicity: do similar phenotypes indicate a common mode of action? A comparison of fetal alcohol syndrome, toluene embryopathy and maternal phenylketonuria, *Toxicol. Lett.* 127 (2002) 197–205.
- [12] E.R. Danielsen, B. Ross, *Magnetic Resonance Spectroscopy Diagnosis of Neurological Diseases*, Marcel Dekker, Inc, New York, NY, 1999.
- [13] V. Delaney-Black, C. Covington, T. Templin, J. Ager, S. Martier, S. Compton, R. Sokol, Prenatal coke: what's behind the smoke? Prenatal cocaine/alcohol exposure and school-age outcomes: the SCHOO-BE experience, *Ann. N.Y. Acad. Sci.* 846 (1998) 277–288.
- [14] V. Delaney-Black, C. Covington, T. Templin, J. Ager, S. Martier, R. Sokol, Prenatal cocaine exposure and child behavior, *Pediatrics* 102 (1998) 945–950.
- [15] V. Delaney-Black, C. Covington, T. Templin, T. Kershaw, B. Nordstrom-Klee, J. Ager, N. Clark, A. Surendran, S. Martier, R.J. Sokol, Expressive language development of children exposed to cocaine prenatally: literature review and report of a prospective cohort study, *J. Commun. Disord.* 33 (2000) 463–480.
- [16] M.J. Druse, Effects of perinatal alcohol exposure on neurotransmitters, membranes, and proteins, in: J.R. West (Ed.), *Alcohol and Brain Development*, Oxford University Press, Oxford, England, 1986, pp. 343–372.
- [17] M.J. Druse, Effects of in utero ethanol exposure on the development of neurotransmitter systems, in: M.W. Miller (Ed.), *Development of the Central Nervous System: Effects of Alcohol and Opiates*, Wiley-Liss, Inc, Hoboken, NJ, 1992, pp. 139–167.
- [18] S. Durston, H.E. Hulshoff Pol, B.J. Casey, J.N. Giedd, J.K. Buitelaar, H. van Engeland, Anatomical MRI of the developing human brain: what have we learned? *J. Am. Acad. Child Adolesc. Psychiatry* 40 (2001) 1012–1020.
- [19] J.H. Duyn, J. Gillen, G. Sobering, P.C.M. van Zijl, C.T.W. Moonen, Multisection proton MR spectroscopic imaging of the brain, *Radiology* 188 (1993) 277–282.
- [20] D. Ebert, O. Speck, A. Konig, M. Berger, J. Hennig, F. Hohagen, 1H-magnetic resonance spectroscopy in obsessive-compulsive disorder: evidence for neuronal loss in the cingulate gyrus and the right striatum, *Psychiatry Res.* 74 (1997) 173–176.
- [21] P.A. Filipek, Structural variations in measures in the developmental disorders, in: R.W. Thatcher, G.R. Lyon, J. Rumsey, N. Krasnegor (Eds.), *Developmental Neuroimaging: Mapping the Development of Brain and Behavior*, Academic Press, San Diego, CA, 1997, pp. 169–186.

- [22] C.G. Filippi, A.M. Ulug, M.D.F. Deck, R.D. Zimmerman, L.A. Heier, Developmental delay in children: assessment with proton MR spectroscopy, *AJNR Am. J. Neuroradiol.* 23 (2002) 882–888.
- [23] K.D. Fitzgerald, G.J. Moore, L.A. Paulson, C.M. Stewart, D.R. Rosenberg, Proton spectroscopic imaging of the thalamus in treatment-naïve pediatric obsessive-compulsive disorder, *Biol. Psychiatry* 47 (2000) 174–182.
- [24] R. Greenbaum, I. Nulman, J. Rovet, G. Koren, The Toronto experience in diagnosing alcohol-related neurodevelopmental disorder: a unique profile of deficits and assets, *Can. J. Clin. Pharmacol.* 9 (2002) 215–225.
- [25] J.H. Hannigan, S. Randall, Behavioral pharmacology in animals exposed prenatally to alcohol, in: E.L. Abel (Ed.), *Fetal Alcohol Syndrome: From Mechanisms to Prevention*, CRC Press, Boca Raton, FL, 1996.
- [26] H.E. Hoyme, P.A. May, W.O. Kalberg, P. Kodituwakku, J.P. Gossage, P.M. Trujillo, D.G. Buckley, J.H. Miller, A.S. Aragon, N. Khaole, D.L. Viljoen, K.L. Jones, L.K. Robinson, A practical clinical approach to diagnosis of fetal alcohol spectrum disorders: clarification of the 1996 institute of medicine criteria, *Pediatrics* 115 (2005) 39–47.
- [27] S.W. Jacobson, Specificity of neurobehavioral outcomes associated with prenatal alcohol exposure, *Alcohol Clin. Exp. Res.* 22 (1998) 313–320.
- [28] S.W. Jacobson, J.L. Jacobson, R.J. Sokol, S.S. Martier, J.W. Ager, M.G. Kaplan, Maternal recall of alcohol, cocaine, and marijuana use during pregnancy, *Neurotoxicol. Teratol.* 13 (1991) 535–540.
- [29] S.W. Jacobson, J.L. Jacobson, R.J. Sokol, S.S. Martier, J.W. Ager, Prenatal alcohol exposure and infant information processing ability, *Child Dev.* 64 (1993) 1706–1721.
- [30] J.L. Jacobson, S.W. Jacobson, S.S. Sokol, J.W. Martier, M.G. Ager, Teratogenic effects of alcohol on infant development, *Alcohol Clin. Exp. Res.* 17 (1993) 174–183.
- [31] S.W. Jacobson, J.L. Jacobson, R.J. Sokol, Effects of fetal alcohol exposure on infant reaction time, *Alcohol Clin. Exp. Res.* 18 (1994) 1125–1132.
- [32] S.W. Jacobson, L.M. Chiodo, J.L. Jacobson, R.J. Sokol, Validity of maternal report of alcohol, cocaine, and smoking during pregnancy in relation to infant neurobehavioral outcome, *Pediatrics* 109 (2002) 815–825.
- [33] S.W. Jacobson, J.L. Jacobson, R.J. Sokol, L.M. Chiodo, R. Corobana, Maternal age, alcohol abuse history, and quality of parenting as moderators of the effects of prenatal alcohol exposure on 7.5-year intellectual function, *Alcohol Clin. Exp. Res.* 28 (2004) 1732–1745.
- [34] M.S. Keshavan, S. Anderson, C. Beckwith, K. Nash, J.W. Pettegrew, K.R. Krishnan, A comparison of stereology and segmentation techniques for volumetric measurements of lateral ventricles in magnetic resonance imaging, *Psychiatry Res.* 61 (1995) 53–60.
- [35] R.A. Komoroski, C. Heimberg, D. Cardwell, C.N. Karson, Effects of gender and region on proton MRS of normal human brain, *Magn. Reson. Imaging* 17 (1999) 427–433.
- [36] H.V. Konovalov, N.S. Kovetsky, Y.V. Bobryshev, K.W.S. Ashwell, Disorders of brain development in the progeny of mothers who used alcohol during pregnancy, *Early Hum. Dev.* 48 (1997) 153–166.
- [37] D. Lopez-Tejero, I. Ferrer, M. Llobera, E. Herrera, Effects of prenatal ethanol exposure on physical growth, sensory reflex maturation and brain development in the rat, *Neuropathol. Appl. Neurobiol.* 12 (1986) 251–260.
- [38] S.E. Maier, J.R. West, Drinking patterns and alcohol-related birth defects, *Alcohol Res. Health* 25 (2001) 168–174.
- [39] S.E. Maier, W.A. Chen, J.A. Miller, J.R. West, Fetal alcohol exposure and temporal vulnerability: regional differences in alcohol-induced microencephaly as a function of the timing of binge-like alcohol exposure during rat brain development, *Alcohol Clin. Exp. Res.* 21 (1997) 1418–1428.
- [40] S.N. Mattson, E.P. Riley, A review of the neurobehavioral deficits in children with fetal alcohol syndrome or prenatal exposure to alcohol, *Alcohol Clin. Exp. Res.* 22 (1998) 279–294.
- [41] S.N. Mattson, E.P. Riley, T.L. Jernigan, C.L. Ehlers, D.C. Delis, K.L. Jones, C. Stern, K.A. Johnson, J.R. Hesselink, U. Bellugi, Fetal alcohol syndrome: a case report of neuropsychological, MRI, and EEG assessment of two children, *Alcohol Clin. Exp. Res.* 16 (1992) 1001–1003.
- [42] S.N. Mattson, E.P. Riley, T.L. Jernigan, A. Garcia, W.M. Kaneko, C.L. Ehlers, K.L. Jones, A decrease in the size of the basal ganglia following prenatal alcohol exposure: a preliminary report, *Neurotoxicol. Teratol.* 16 (1994) 283–289.
- [43] S.N. Mattson, E.P. Riley, E.R. Sowell, T.L. Jernigan, D.F. Sobel, K.L. Jones, A decrease in the size of the basal ganglia in children with fetal alcohol syndrome, *Alcohol Clin. Exp. Res.* 20 (1996) 1088–1093.
- [44] S.N. Mattson, E.P. Riley, L. Gramling, D.C. Delis, K.L. Jones, Neuropsychological comparison of alcohol-exposed children with or without physical features of fetal alcohol syndrome, *Neuropsychology* 12 (1998) 146–153.
- [45] G.J. Moore, Proton magnetic resonance spectroscopy in pediatric neuroradiology, *Pediatr. Radiol.* 28 (1998) 805–814.
- [46] G.J. Moore, M.P. Galloway, Magnetic resonance spectroscopy: neurochemistry and treatment effects in affective disorders, *Psychopharmacol. Bull.* 36 (2002) 5–23.
- [47] J.H. Neale, R.T. Olszewski, L.M. Gehl, B. Wroblewska, T. Bzdega, The neurotransmitter *N*-acetylaspartyl-glutamate in models of pain, ALS, diabetic neuropathy, CNS injury and schizophrenia, *Trends Pharmacol. Sci.* 26 (2005) 477–484.
- [48] E.D. O'Hare, E. Kan, J. Yoshii, S.N. Mattson, E.P. Riley, P.M. Thompson, A.W. Toga, E.R. Sowell, Mapping cerebellar vermal morphology and cognitive correlates in prenatal alcohol exposure, *Neuroreport* 16 (2005) 1285–1290.
- [49] H.C. Olson, J.J. Feldman, A.P. Streissguth, P.D. Sampson, F.L. Bookstein, Neuropsychological deficits in adolescents with fetal alcohol syndrome: clinical findings, *Alcohol Clin. Exp. Res.* 22 (1998) 1998–2012.
- [50] K.D. O'Malley, J. Nanson, Clinical implications of a link between fetal alcohol spectrum disorder and attention-deficit hyperactivity disorder, *Can. J. Psychiatry* 47 (2002) 349–354.
- [51] P.J. Pouwels, J. Frahm, Regional metabolite concentrations in human brain as determined by quantitative localized proton MRS, *Magn. Reson. Med.* 39 (1998) 53–60.
- [52] E.P. Riley, C.L. McGee, Fetal alcohol spectrum disorders: an overview with emphasis on changes in brain and behavior, *Exp. Biol. Med.* 230 (2005) 357–365.
- [53] E.P. Riley, S.N. Mattson, E.R. Sowell, T.L. Jernigan, D.F. Sobel, K.L. Jones, Abnormalities of the corpus callosum in children prenatally exposed to alcohol, *Alcohol Clin. Exp. Res.* 19 (1995) 1198–1202.
- [54] E.P. Riley, C.L. McGee, E.R. Sowell, Teratogenic effects of alcohol: a decade of brain imaging, *Am. J. Med. Genet.* 127 (2004) 35–41.
- [55] T.M. Roebuck, S.N. Mattson, E.P. Riley, A review of the neuroanatomical findings in children with fetal alcohol syndrome or prenatal exposure to alcohol, *Alcohol Clin. Exp. Res.* 22 (1998) 339–344.
- [56] M. Russell, S.S. Martier, R.J. Sokol, P. Mudar, S. Bottoms, S. Jacobson, J. Jacobson, Screening for pregnancy risk-drinking, *Alcohol Clin. Exp. Res.* 18 (1994) 1156–1161.
- [57] M. Russell, S.S. Martier, R.J. Sokol, P. Mudar, S. Jacobson, J. Jacobson, Detecting risk drinking during pregnancy: a comparison of four screening questionnaires, *Am. J. Public Health* 86 (1996) 1435–1439.
- [58] A. Russell, B. Cortese, E. Lorch, J. Ivey, S.P. Banerjee, G.J. Moore, D.R. Rosenberg, Localized functional neurochemical marker abnormalities in dorsolateral prefrontal cortex in pediatric obsessive-compulsive disorder, *J. Child Adolesc. Psychopharmacol.* 13 (2003) S31–S38.
- [59] P.D. Sampson, A.P. Streissguth, F.L. Bookstein, R.E. Little, S.K. Clarren, P. Dehaene, J.W. Hanson, J.M. Graham Jr., Incidence of fetal alcohol syndrome and prevalence of alcohol-related neurodevelopmental disorder, *Teratology* 56 (1997) 317–326.
- [60] M.L. Selzer, The Michigan Alcohol Screening Test: the quest for a new diagnostic instrument, *Am. J. Psychiatry* 127 (1971) 1653–1658.
- [61] B.J. Soher, P.C.M. van Zijl, J.H. Duyn, P.B. Barker, Quantitative proton MR spectroscopic imaging of the human brain, *Magn. Reson. Med.* 35 (1996) 356–363.
- [62] R.J. Sokol, S. Martier, C. Ernhart, Identification of alcohol abuse in the prenatal clinic, NIAAA Alcohol, Drug Abuse, and Mental Health Administration, *Res. Monogr.* 17 (1985) 209–227.
- [63] R.J. Sokol, S.S. Martier, J.W. Ager, The T-ACE questions: practical prenatal detection of risk-drinking, *Am. J. Obstet. Gynecol.* 160 (1989) 863–868.
- [64] B. Sood, V. Delaney-Black, C. Covington, B. Nordstrom-Klee, J. Ager, T. Templin, J. Janisse, S. Martier, R.J. Sokol, Prenatal alcohol exposure and

- childhood behavior at age 6 to 7 years: I. Dose-response effect, *Pediatrics* 108 (2001) e34.
- [65] E.R. Sowell, T.L. Jernigan, S.N. Mattson, E.P. Riley, D.F. Sobel, K.L. Jones, Abnormal development of the cerebellar vermis in children prenatally exposed to alcohol: size reduction in lobules I–V, *Alcohol Clin. Exp. Res.* 20 (1996) 31–34.
- [66] K. Stratton, C. Howe, F. Battaglia, *Fetal Alcohol Syndrome: Diagnosis, Epidemiology, Prevention, and Treatment*, Institute of Medicine National Academy Press, Washington, DC, 1996.
- [67] A.P. Streissguth, K. O'Malley, Neuropsychiatric implications and long-term consequences of fetal alcohol spectrum disorders, *Semin. Clin. Neuropsychiatry* 5 (2000) 177–190.
- [68] A.P. Streissguth, J.M. Aase, S.K. Clarren, S.P. Randels, R.A. LaDue, D.F. Smith, Fetal alcohol syndrome in adolescents and adults, *JAMA* 265 (1991) 1961–1967.
- [69] A.P. Streissguth, H.M. Barr, P.D. Sampson, F.L. Bookstein, Prenatal alcohol and offspring development: the first fourteen years, *Drug Alcohol Depend.* 36 (1994) 89–99.
- [70] A.P. Streissguth, F.L. Bookstein, P.D. Sampson, H.M. Barr, Attention: prenatal alcohol and continuities of vigilance and attentional problems from 4 through 14 years, *Dev. Psychopathol.* 7 (1995) 419–446.
- [71] K.K. Sulik, Genesis of alcohol-induced craniofacial dysmorphism, *Exp. Biol. Med.* 230 (2005) 366–375.
- [72] T.S. Wass, W.H. Persutte, J.C. Hobbins, The impact of prenatal alcohol exposure on frontal cortex development in utero, *Am. J. Obstet. Gynecol.* 185 (2001) 737–742.
- [73] K. Wisniewski, M. Damska, J.H. Sher, Q. Qazi, A clinical neuropathological study of the fetal alcohol syndrome, *Neuropediatrics* 14 (1983) 197–201.